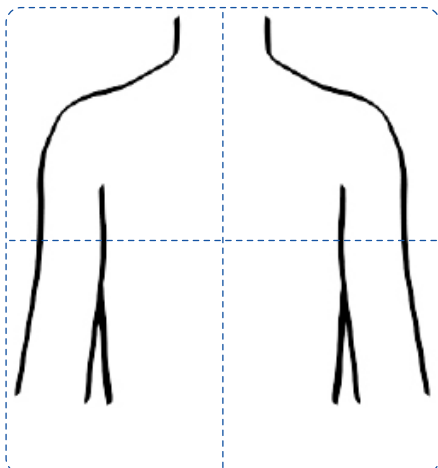


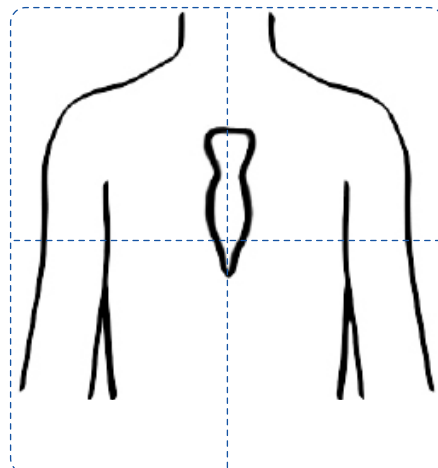
STEP 1.

Draw outline



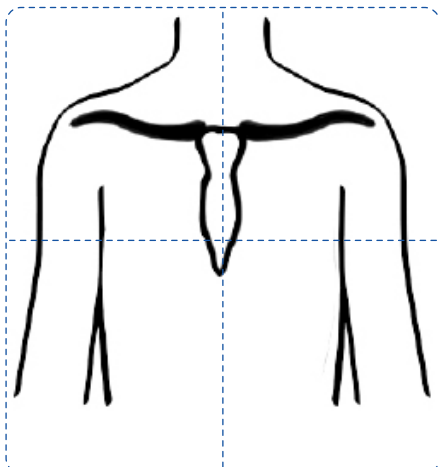
STEP 2.

Draw sternum



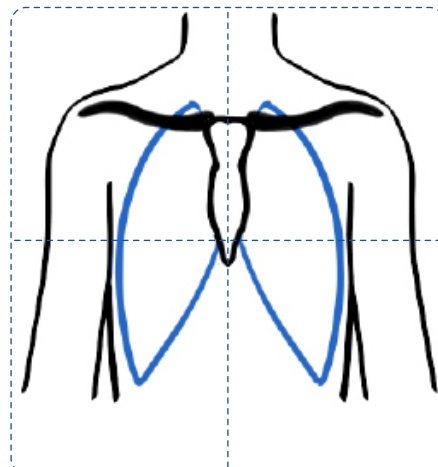
STEP 3.

Draw clavicals



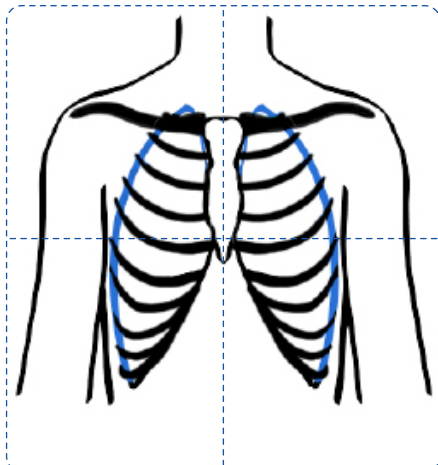
STEP 4.

Draw lungs



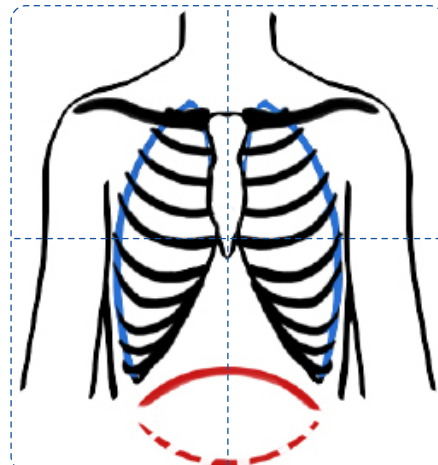
STEP 5.

Draw ribs



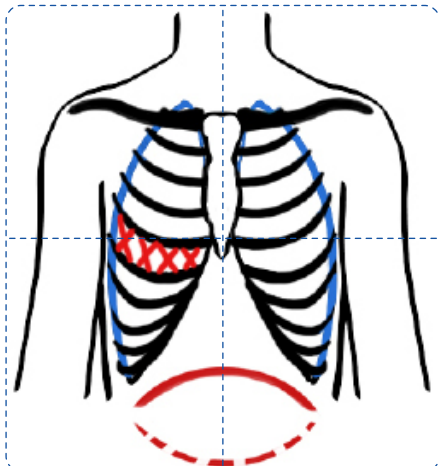
STEP 6.

Draw diaphragm



STEP 7.

Identify intercostal muscle



STEP 8.

Draw sternocleidomastoid muscle

